

Effect of piperazine citrate on experimentally *Cryptosporidium parvum* infected mice

Abstract

Background : Nitazoxanide has not been found to be effective in (Acquired Immunodeficiency Syndrome) patients. Piperazine-derivative MMV665917 may potentially be used to treat human cryptosporidiosis, however further investigations are required.

Purpose: The aim of this work was to evaluate the effect of piperazine citrate on *Cryptosporidium parvum* infected mice.

Methods: Stool samples would be collected from patients attending Abu-Elrish hospital, showing *Cryptosporidium parvum* oocyst. One hundred and thirty mice, were selected from (Theodor Bilharz Research Institute). Half of them would take (dexamethasone) for 15 day before infection. Both Nitazoxanide (100mg/kg) and piperazine citrate at different doses (20, 30, 40 mg/kg) were given to the mice. Assessment of drugs effect was done by parasitological and histopathological assessment.

Results: the highest reduction in mean oocysts number of *Cryptosporidium parvum* was achieved by group treated with combination (nitazoxanide + piperazine 30) therapy for 1 week in immunocompromised group (95%) and immunocompetent group (89%) and remarkable regression of histopathological alterations was noticed in ileum of immunocompromised mice treated with combination, when compared with ileum of immunocompromised (positive control) group which showed remarkable histopathological changes exhibited as shortening of the intestinal villi, hyperplasia of goblet cells, inflammatory cells infiltration in the lamina propria, submucosa and edema in the submucosa, multiple *Cryptosporidium* oocyst.

Conclusion: Administration of (piperazine 30+ nitazoxanide) for 7 days in immunocompromised group gave the highest reduction rate of mean number of oocysts and remarkable regression of histopathological alterations.

Keywords: *Cryptosporidium*, nitazoxanide, piperazine citrate.

Introduction

Cryptosporidium is a genus of apicomplexan parasites that can cause gastrointestinal illness (cryptosporidiosis) in both immunocompetent and immunodeficient human [1]. *Cryptosporidium* is the second major cause of moderate to severe diarrhea in children younger than two and an important cause of mortality worldwide [2]. Most infections are self-limited in immunocompetent but may be associated with complications in high risk patients [3].

Nitazoxanide is the only approved drug for treatment of diarrhea caused by *Cryptosporidium* infection [4]. But, it showed imperfect efficacy in the most vulnerable patients. Besides, the dependence of a one drug as sole effective treatment for any microorganism is known to carry an inevitable risk of electing resistant strains and failure of treatment. Hence, development of new effective drug for cryptosporidiosis represents a pressing need [5].

Nitazoxanide has not been found to be effective in AIDS patients [6]. Several enzymes have been identified as potential drug targets, including calcium-dependent protein kinases [7], cysteine proteases [8], inosine monophosphate dehydrogenase [9] and the folate biosynthesis pathway [10]. Other studies are testing compounds repurposed, which were developed for other indications. However, none of these compounds have made it into clinical trials [10].

Piperazine citrate, anthelmintic belongs to class of drugs called Adrenergic agonists. It works by paralyzing the worms and making them to pass in the stool. It is effective against the intestinal nematodes' roundworm (*Ascaris lumbricoides*), pinworm and threadworm (*Enterobius vermicularis*). Piperazine produces a neuromuscular block leads to muscle paralysis of the worms which are consequently dislodged and expelled in the feces [11].

Piperazine-derivative MMV665917 may potentially be used to treat human cryptosporidiosis, however further investigations are required [12].

Purpose

The aim of this study was to evaluate the parasitological and histopathological effect of piperazine citrate on *Cryptosporidium parvum* infected mice.

Material and method

I-Place of the work:

This experimental study was done in Medical Parasitology department, Faculty of Medicine, Banha University and Theodor Bilharz Research Institute, Cairo, Egypt. From August 2020 to October 2020.

II-Drugs:

A- Piperazine citrate powder for oral suspension.

- Previous recommended dose of 20 mg/kg [12]

- Another dose 30mg/kg

- Another dose 40mg/kg.

B- Nitazoxanide (class of drug known thiazolides) (nitazode)

Syrup 100 mg/5ml .

C- Administration of (Piperazine 30mg/kg + NTZ) in combination

III- Parasite:

Stool samples would be collected from infected patients attending Abu-Elrish children hospital , showing *cryptosporidium parvum* oocyst.

IV-Experimental animal:

Inclusion criteria :This experimental study was done on one hundred and thirty bred male swiss albino mice (**Fig1**). approximately 20 gm , 6-8 weeks-old, , were selected from animal house of TBRI. Half of them would take (dexamethasone) for 15 day before infection .Half of them would take immunosuppressive drug (dexamethasone) for 15 day before infection (**Fig1**). . Mice would be maintained in air conditioned quarters and provided with suitable food and water.

Exclusion criteria :Diseased mice or drug injected mice should be excluded .

V-Experimental design:

In addition to the control groups , mice were divided into two major Immunocomptent and immunocompromised groups (**Fig1**).

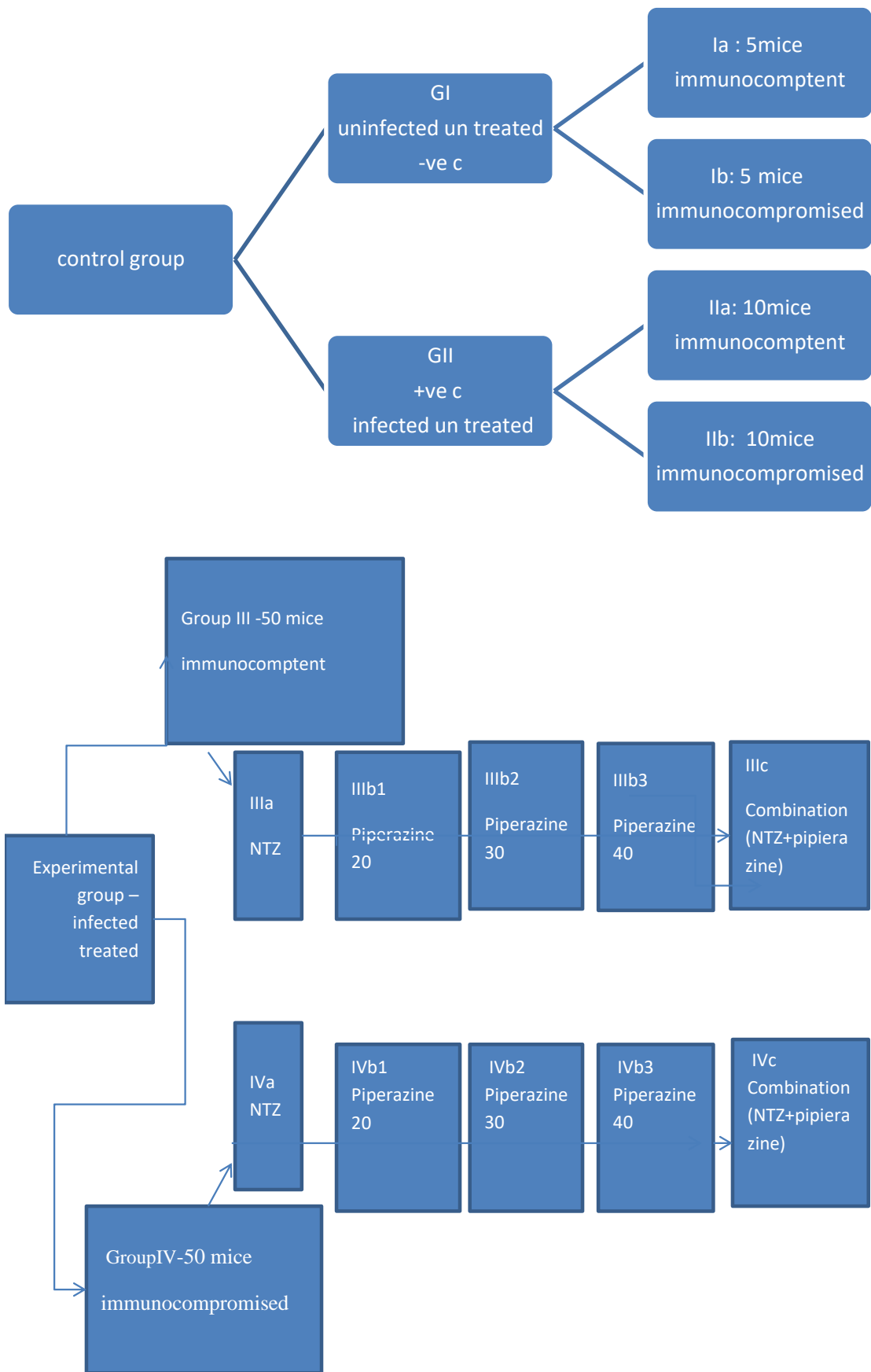


Figure (1): control and experimental groups.

Assessment of drugs effect:

- parasitological assessment by feces examination for confirmation of the presence of oocysts by Modified Zeil Nelseen stain method [13], calculation of mean number of oocysts, then calculation of reduction rate from the mean by equation. $RR = (\text{mean of control} - \text{mean of group}) / \text{mean of control}$ then multiply by 100.

- Histopathological examination of intestinal tissue(H &E) according to [14].

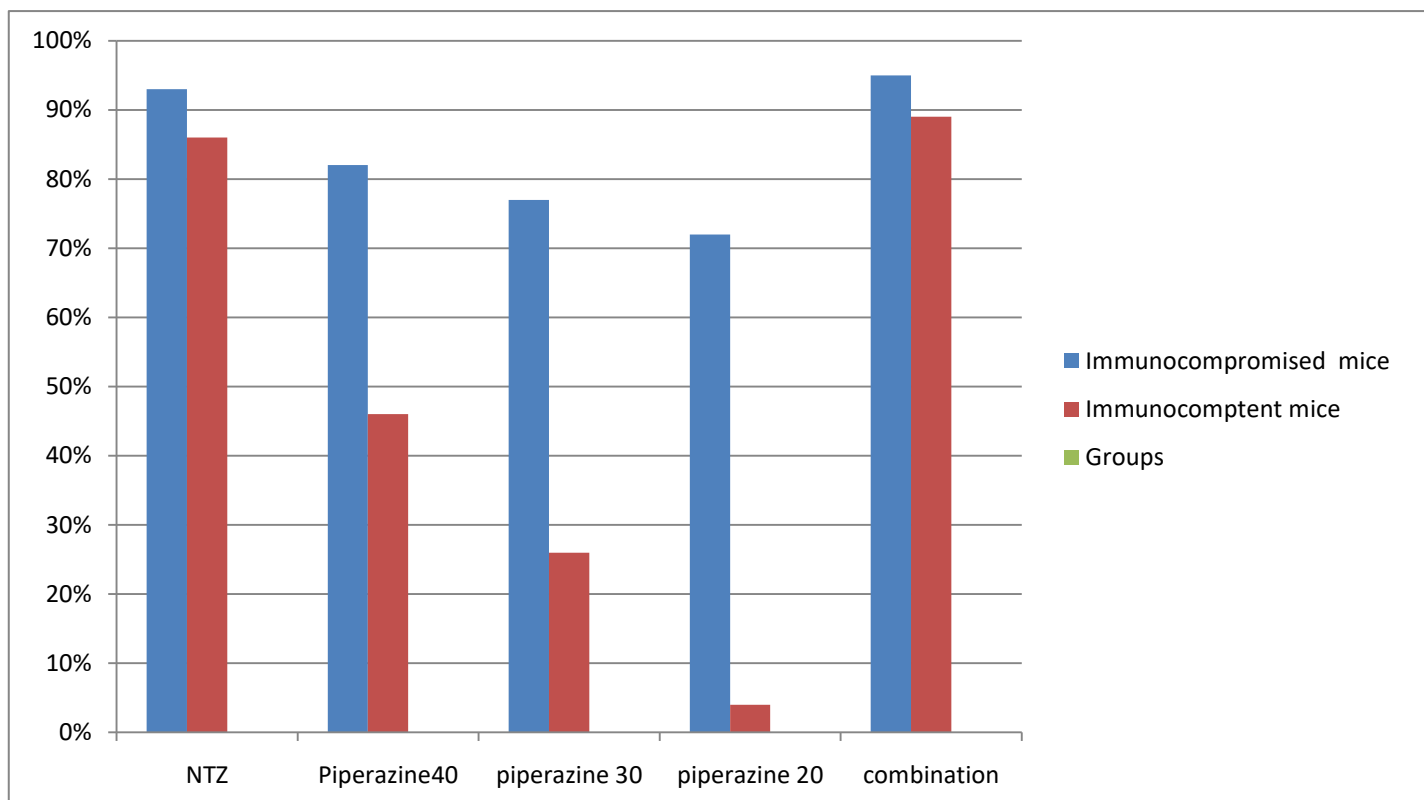
The ileum of every mouse was obtained. The ileums of each mice group were fixed in 10% formalin for histopathological study

Ethical consideration: All the animal experiments were performed according to the rules of the Scientific Research Ethical Committee, Faculty of Medicine Benha University. Also, animal handling and all procedures were done in agreement with the TBRI ethical guidelines.

Results

Table1 and chart 1: Comparison between the effect of piperazine citrate and nitazoxanide on the reduction rate of *Cryptosporidium parvum* oocysts in feces of immunocompetent and immunocompromised infected mice.

Groups	reduction%		reduction%	
	Immunocomptent mice		Immunocompromised mice	
(NTZ)	IIIa	86%	IVa	93%
(Piperazine40)	III b1	46%	IVb1	82%
(Piperazine30)	IIIb2	26%	IVb2	77%
(Piperazine20)	IIIb3	4%	IVb3	72%
(NTZ+piperazine30)	IIIc	89%	IVc	95%



Our results showed that the highest reduction in mean oocysts number of *Cryptosporidium parvum* was achieved by group treated with combination therapy for one week in immunocompromised group (95%) and immunocompetent group (89%), followed by two groups treated with nitazoxanide 5 days in both immunocompetent and immunocompromised group (86-93%), followed by 2 groups treated by piperazine 40 mg/kg 7 days in both immunocompetent and immunocompromised group (82-46%), followed by 2 groups treated by piperazine 30 mg/kg 7 days in both immunocompetent and immunocompromised group (26-77%). Inversely was the group treated with piperazine citrate 20 mg/kg for 7 days which showed the lowest rate for mean oocysts number reduction among all groups (4%) in immunocompetent group and (72%) in immunocompromised group (**table 1 and chart1**).

table (2): Comparison between different tested groups according to histopathological changes.

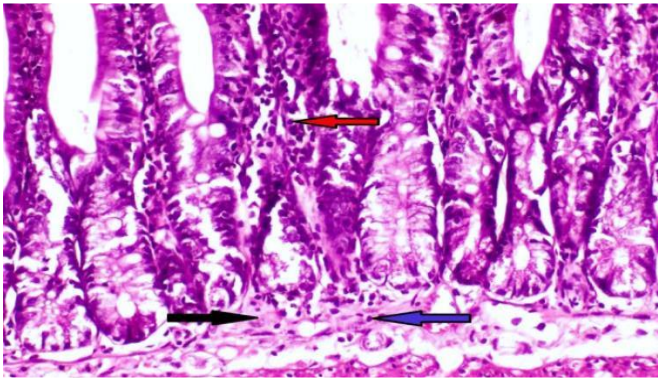
Groups	Immunocompetent group							Immunocompromised group						
	Ia	IIa	IIIa	IIIb1	IIIb2	IIIb3	IIIc	Ib	IIb	IVa	IVb1	IVb2	IVb3	IVc
shortening of intestinal villi	0	2	0	1	1	1	0	2	3	0	2	1	0	0
hyperplasia of intestinal villi	0	2	0	2	1	0	0	1	2	1	2	1	1	1
hyperplasia of goblet cells	0	3	1	1	1	1	0	0	3	0	1	2	1	1
inflammatory cells infiltration	0	3	2	2	1	1	1	1	3	2	2	2	1	1
Edema	0	2	0	1	2	1	1	1	3	2	1	1	1	1
Necrosis of crypts	0	2	1	2	1	0	0	0	2	1	2	2	0	0
Cryptosporidium oocyst	0	2	0	1	1	0	0	0	3	1	2	1	1	0

0) indicated no changes (1) indicated mild change

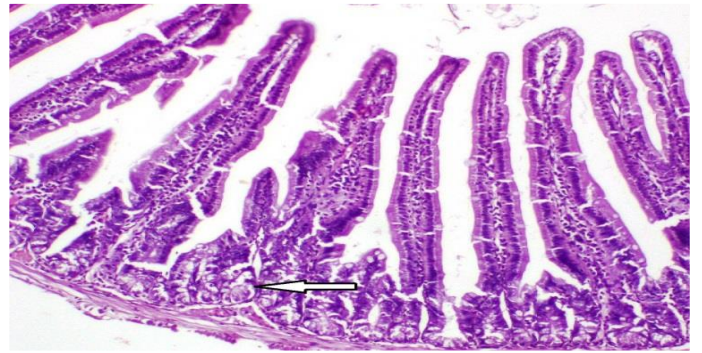(2) indicated moderate changes (3) indicated severe changes

The pathological picture of examined ilium of different groups were in the form of shortening and hyperplasia of intestinal villi with hyperplasia of goblet cells, inflammatory cells infiltration in the lamina propria and submucosa., oedema , necrosis of crypts and prescence of cryptosporidium oocyst attached to the brush border of the epithelial cells of intestinal villi. The severity of these finding varied from one group to another **(Table2-Fig2&3)**

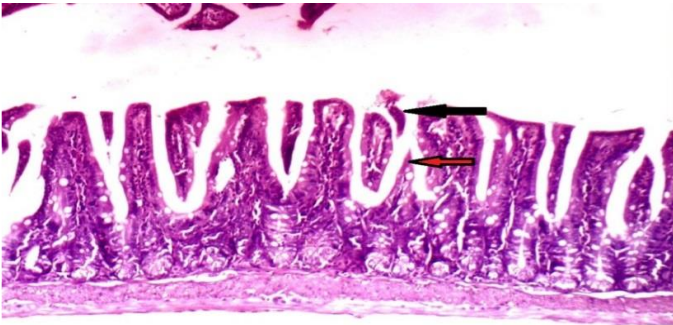
Histopathological examination of infected immunocompromised mice ileum by H&E.



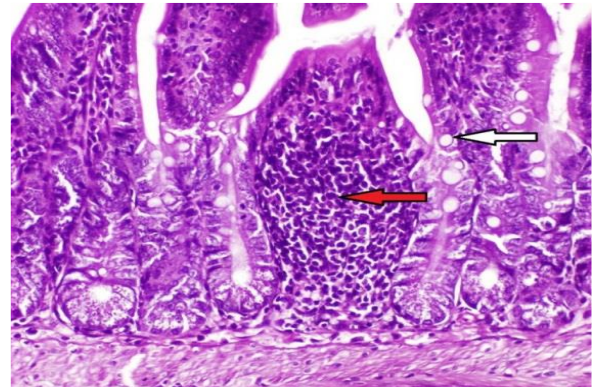
A



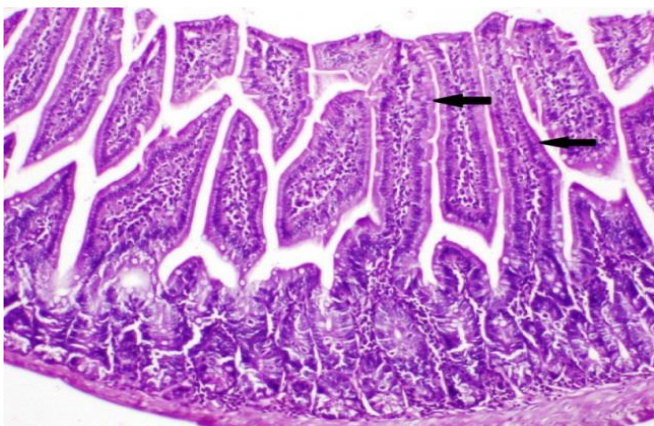
B



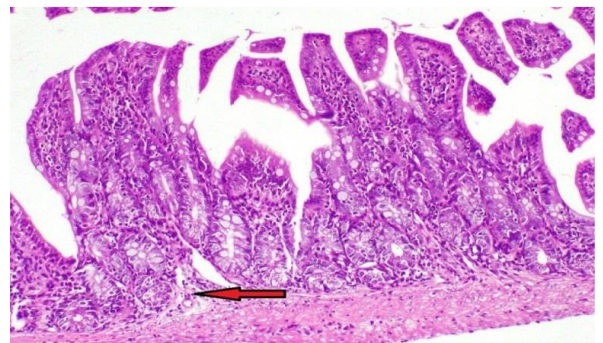
C



D



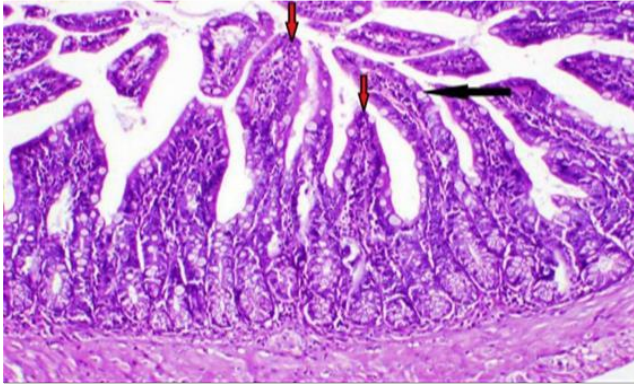
E



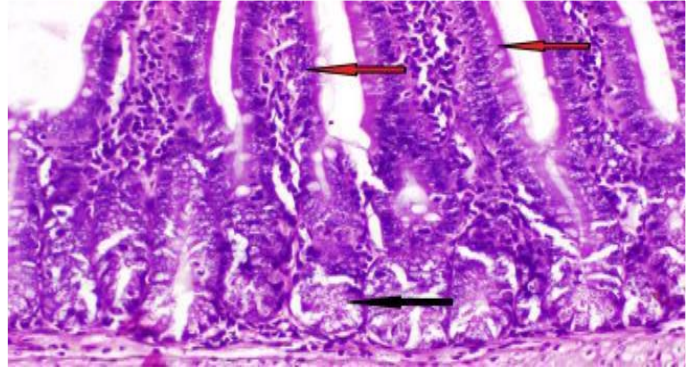
F

Fig (2): Histopathological studies intestinal tissue showed. (A): Photomicrograph of ileum of Cryptosporidium infected mice (Positive infected with Dexamethsone (D)) showing inflammatory cells infiltration in the lamina propria (red arrow), submucosa (black arrow) and edema in the submucosa (blue arrow) (H & E X 200). (B): Photomicrograph of ileum of NTZD treated mice showing normal intestinal villi and necrosis of some intestinal glands (white arrow)(H & E X 200 (C): Photomicrograph of ileum of Piperazine 20D treated mice showing shortening and hyperplasia of intestinal villi (red arrows), necrosis and sloughing of the apical part of intestinal villi (black arrow) (H & E X 100). (D): Photomicrograph of ileum of Piperazine 30D treated mice showing hyperplasia of goblet cells (white arrow) and focal inflammatory cells infiltration in the lamina propria and submucosa (red arrow) (H & E X 200). (E): Photomicrograph of ileum of Piperazine 40D treated mice showing slight hyperplasia of intestinal villi (black arrow) (H & E X 100) . (F): Photomicrograph of ileum of combination D treated mice showing slight edema the in submucosa (red arrow)(H & E X 100) .

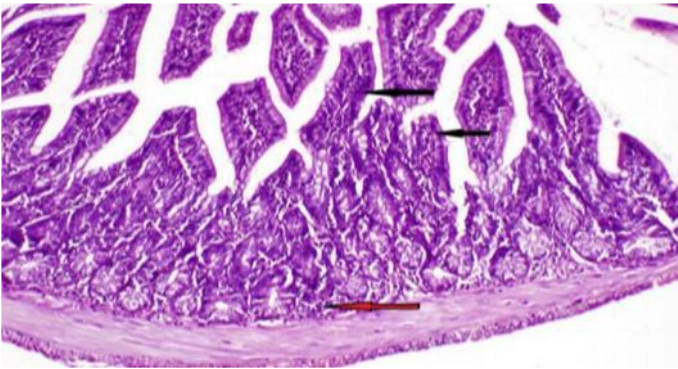
Histopathological examination of immunocompetent infected mice ileum by using H and E stain.



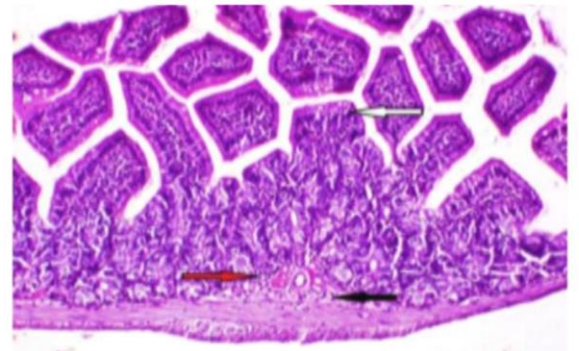
G



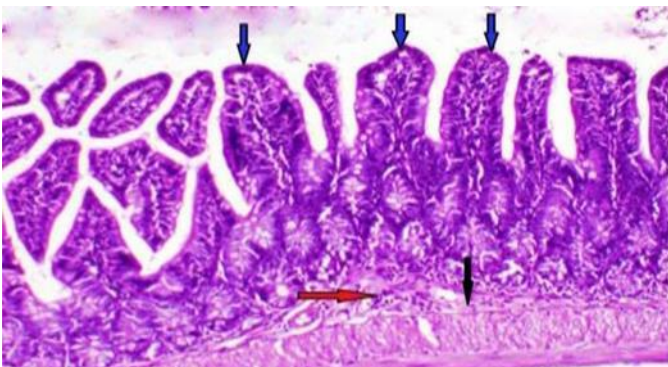
H



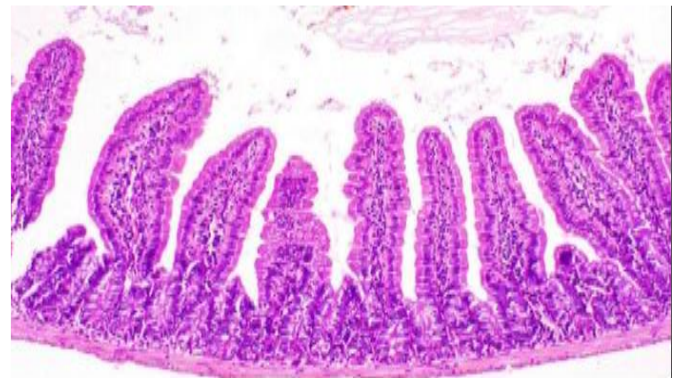
I



J



K



L

Fig (3): Histopathological studies intestinal tissue showed (G): Photomicrograph of ileum of *Cryptosporidium* infected mice (Positive control) showing hyperplasia of goblet cells (black arrow) and hyperplasia of intestinal villi (red arrow) (H & E X 100).. (H): Photomicrograph of ileum of NTZ treated mice showing normal intestinal villi (red arrow) and necrosis of some intestinal glands (black arrow)(H & E X 200). (I): Photomicrograph of ileum of Piperazin 20 treated mice showing thickening, shortening and hyperplasia of intestinal villi (black arrows) as well as focal inflammatory cells infiltration in the submucosa (red arrow) (H & E X 100). (J): Photomicrograph of ileum of Piperazin 30 treated mice showing thickening and shortening of intestinal villi (white arrow), slight edema (black arrow) and few inflammatory cells infiltration in the submucosa (red arrow) (H & E X 100). (K): Photomicrograph of ileum of Piperazin 40 treated mice showing slight shortening of the intestinal villi (blue arrow), slight edema (black arrow) and few inflammatory cells infiltration in the submucosa (red arrow) (H & E X 100). (L): Photomicrograph of ileum of combination treated mice showing the normal histological architecture. Note normal villi, crypts and muscularis layers (H & E X 100).

Discussion

Cryptosporidiosis is a life-threatening in persons with human immunodeficiency virus and also in young children in the developing world [15]. In children, cryptosporidiosis causes severe diarrhea, excess mortality, stunting and malnutrition [16]. There is a huge unmet need for *Cryptosporidium* drugs [17]. Only nitazoxanide is licensed for treatment of cryptosporidiosis, but it has not shown any benefits as a treatment for immunocompromised patients [6]. Nitazoxanide has been licensed by the U.S. Food and Drug Administration for the treatment of cryptosporidiosis in patients with strong TH-1 response but has not demonstrated adequate results in defective patients [18]. The lack of successful cryptosporidiosis therapies and vaccinations conserves a cycle of infection, malnutrition and immunosuppression [19] which can lead to a spectrum of conditions sometimes termed as "environmental enteropathy" [20]. Limited treatment options also pose a major challenge to public health, giving the significant burden of disease.

The identification of MMV665917 as a novel piperazine-based lead compound for the treatment of cryptosporidiosis. It is active against *C. hominis* and field isolates of *C. parvum*, shows no *in vitro* cytotoxicity at high concentrations, and, in agreement with previously published data on the MMV Malaria Box, is highly specific for *Cryptosporidium* parasites and blood-stage *Plasmodium* species [21].

The clinical and microbiologic anti-*Cryptosporidium* efficacy of the piperazine-based compound MMV665917 was demonstrated in neonatal calves. Oral administration of MMV665917 (22 mg/kg once daily) was begun two days after the onset of severe diarrhea and continued for seven days. Treatment resulted in prompt resolution of diarrhea, and reduced total fecal oocyst shedding by ~94%. MMV665917 was useful for treatment, rather than just prophylaxis, since it was safe and effective when administered well after the onset of diarrhea. Furthermore, even though all animals received intensive supportive care, there was a strong trend towards improved secondary health outcomes, including general health, appetite, and dehydration measures amongst treated animals. These data establish MMV665917 as an outstanding lead compound for *Cryptosporidium* drug development [22].

MMV665917 appears to cure established cryptosporidiosis in highly immunocompromised non-obese gamma mice, unlike paromomycin, nitazoxanide, and the recently identified repurposing lead clofazimine. MMV665917 is also highly efficacious in an IFN- γ KO mouse model of acute infection.

MMV665917 appeared to be parasitocidal and resulted in parasite elimination over time, while nitazoxanide, paromomycin, and clofazimine all appeared to be parasitostatic. These features of MMV665917 and the methods used to define them provide guidance for further development of this piperazine-based compound series to treat cryptosporidiosis. Given the lack of a clearly defined developmental pathway for anti cryptosporidial, we believe that these studies provide general guidance for *Cryptosporidium* drugdevelopment[23].

Piperazine citrate, anthelmintic belongs to class of drugs called Adrenergic agonists. It works by paralyzing the worms and making them to pass in the stool. It is effective against the intestinal nematodes' roundworm (*Ascaris lumbricoides*), pinworm and threadworm (*Enterobius vermicularis*). Piperazine produces a neuromuscular block leads to muscle paralysis of the worms which are consequently dislodged and expelled in the feces [11].

Piperazine citrate as a derivative of piperazine drugs have never been studied in *Cryptosporidium*. The present study was undertaken to evaluate the anti cryptosporidial effect of it on experimentally *Cryptosporidium parvum* infected mice.

Regarding piperazine citrate different doses in both immunocompetent and immunocompromised group , the group which was treated by combination of piperazine citrate 30 mg/kg and nitazoxanide 100 mg/kg for 7 days gave obvious therapeutic effect in treating cryptosporidiosis. In this studied group, the mean oocysts number reduction rate was (89-95%) (**Table1**). This came in correlation with histopathological findings which showed remarkable regression of histopathological alterations. It was noticed in ileum of mice which were treated with the combined drugs. The examined sections from this group exhibited the normal histological architecture (normal villi, crypts and muscularis layers. Otherwise, slight edema in the submucosa was seen in some examined sections (**Fig2**).

The group which was treated by nitazoxanide alone showed (86-93%) (**Table1**) reduction rate in Immunocompetent and immunocompromised groups. These results support the histopathological finding in ileum of the mice which were treated with nitazoxanide It showed regression of the histopathological damage, as the examined sections revealed normal intestinal villi , necrosis of some intestinal glands (**Fig3**). Those finding come in agreement with [24] who stated that The histopathology of infected colonic mucosa showed marked improvement and low-grade of dysplasia in the infected and treated group with the combined therapy of (artesunate and nanzoxide) , followed by the group of mice which was treated with NTZ alone which revealed regression of the histopathological damage, as examined sections revealed normal intestinal villi , necrosis of some intestinal glands and focal inflammatory cells infiltration in the lamina propria and submucosa.

Inversely, the group of the mice which was treated with piperazine citrate 20 mg/kg for 7days, showed the lowest rate for mean oocysts number reduction among all groups (4%) in immunocompetent group and (72%)(**Table1**) in immunocompromised group. So the worst histopathological effect was found in ileum of mice which were treated with piperazine 20, in the form of thickening, shortening and hyperplasia of intestinal villi , necrosis of intestinal glands as well as inflammatory cells infiltration in the lamina propria and submucosa(**Fig 2&3**) . These results are in agreement with [30] who demonstrated clearance of

cryptosporidiosis among hospitalized children with paromomycin treatment compared to no treatment. However, the response was significantly less active than with nitazoxanide

The group which was treated by piperazine 40 mg/kg for 7 days in both immunocompetent and immunocompromised group, the reduction rate was (48-82%). According to regression of histopathology of the ileum of the mice which were treated with piperazine 40 come in the third place. It showed slight shortening of the intestinal villi, slight edema and few inflammatory cells infiltration in the submucosa, followed by the group of the mice which were treated by piperazine 30, It showed thickening and shortening of intestinal villi, slight edema and few inflammatory cells infiltration in the submucosa. These results come in parallel to [25] who stated that *C. parvum* oocysts were also abundantly present in mice treated with 20 mg/kg/day of OIPC and intestinal damage was also present but to a lesser extent than in the infected controls. At the dose of 30 mg/kg/day of OIPC, mild intestinal damage and inflammation were noticeable and *C. parvum* oocysts were scarcely visible. Finally, at 40 mg/kg/day, mice displayed practically no signs of intestinal damage or inflammation and a rare presence of *C. parvum* oocysts. In the two groups (immunocompetent and immunocompromised) which were treated by piperazine 30 mg/kg for 7 days, the reduction rate was (26-77%). So these parasitological findings confirm histopathology in our result which showed moderate improved histopathological lesions which were seen in ileum of mice which were treated with piperazine 30, There were thickening and shortening of intestinal villi, slight edema and few inflammatory cells infiltration in the submucosa. Those findings are in parallel [23] to who stated that PiperazineMMV665917 given at 30 mg/kg twice daily reduced oocyst shedding by > 90%. and the least reduction found in group treated with piperazine 20 mg/kg 7 days in both immunocompetent and immunocompromised group (4-72%). Also it come in parallel to [25] who stated that there is a statistical difference ($P < 0.0001$) between OIPC (oleylphosphocholine) treatment and uninfected controls starting at the concentration of 100 nM due to the lack of efficiency of these doses to inhibit *C. parvum* infection. Results demonstrated adose-dependent reduction of *C. parvum* burden when treated with increasing concentrations of OIPC.

In the present study, histopathological examination of the ileum of the mice was used as evaluating parameter to study the efficacy of piperazine citrate. The histological examination of ileum of immunocompromised mice which were infected with *Cryptosporidium*, they showed remarkable histopathological changes (score 3) (Table2) exhibited as shortening of the intestinal villi, hyperplasia of goblet cells, inflammatory cells infiltration in the lamina propria, submucosa and edema in the submucosa, multiple *Cryptosporidium* oocyst attached to the brush border of the epithelial cells of intestinal villi and necrosis of the intestinal crypts. This finding come in parallel to [26] who stated that Histopathological changes in G3 (positive control) gp show severe destruction of intestinal tissue, the villi show atrophy, shortening, fusion, desquamation of epithelial lining layer and infiltration of inflammatory cells in lamina propria.

Those findings are also in parallel to [27] who found that in rats infected with *Cryptosporidium* spp, the ileum showed thickening and flat of the villi, degeneration, atrophy, and necrosis with sloughing of the upper tips of the villi,

inflammatory cellular infiltration in the lamina propria and submucosa with edema in the inner circular and the outer longitudinal muscle. Different developmental stages of *Cryptosporidium* spp. were detected at the brush border of the epithelial cells and crypt of Lieberkühn which showed degenerative changes .

Our results are in agreement with [28] who found that the lesions found during histopathological examination of samples from the ileum and colon which included alterations of the microvillus border of the intestinal epithelium characterized by atrophy, denudation and fusion along with crypt hyperplasia. Thus, the normal cito architecture of enterocytes was conserved on most of the affected mucosa. *Cryptosporidium* spp. infection, represented by different parasitic stages, was limited to the apical pole of the enterocytes, with intracellular extra cytoplasmatic localization. Some infected enterocytes presented vacuolar dystrophy, while in some areas the cells were flattened or cuboidal. These areas alternate with areas of normal enterocytes. Congestion of the affected segments accompanied by a moderate degree of infiltration with lymphocytes, plasma cells, only few neutrophils and eosinophils were found in the lamina propria. On some areas, the enterocytes were undergoing necrosis and degeneration.

Several degrees of inflammatory changes were seen in the groups infected with the parasites, both immunocompetent and immunosuppressed beside dysplasia with different grades [29].

Immunocompromised groups in our results showed the highest reduction rate in all groups (93-82-77-72-95 %) when compared with Immunocomptent groups (86-46-26-4-89 %)(Table1). While histopathological changes are marked in positive control groups ,it is more obvious in immunocompromised positive control group ,may be due to dexamethasone which revealed some histopathological alterations described as shortening and atrophy of the intestinal villi with few inflammatory cells infiltration in the submucosa, edema in lamina propria and few inflammatory cells infiltration in the lamina propria Fig(2). So histopathological score(Table2) is higher in immunocompromised groups than Immunocomptent, which indicate more pathological changes.

Conclusion

Administration of (piperazine 30+ nitazoxanide) for 7days in immunocompromised group gave the highest reduction rate of mean number of oocysts and remarkable, regression of histopathological alterations.

Conflict of interest

None of the contributor declared any conflict of interest.

References

1. **Sponseller, J.K.; Griffiths, J.K. and Tzipori, S . (2014):** "The evolution of respiratory cryptosporidiosis: evidence for transmission by inhalation. *Clinical Microbiology Reviews*;27 (3): 575. Sun, Z,(214); Synthesis, in vitro evaluation and cocrystal structure of 4-oxo-[1]benzopyrano[4,3-c]pyrazole *Cryptosporidium parvum* inosine 5'-monophosphate dehydrogenase (CpIMPDH) inhibitors. *J Med Chem* ;57(24):10544–50.
2. **Bones, A.J.; Jossé, L.; More, C.; Miller, C.N.; Michaelis, M.and Tsaousis, A.D . (2019):** Past and future trends of *Cryptosporidium* in vitro research. *Exp. Parasitol*; 196:28-37.
3. **Wang, R.J.; Li, J.Q.; Chen, Y.C.; Zhang, L.X, and Xiao, L.H.(2018):** Widespread occurrence of *Cryptosporidium* infections in patients with HIV/AIDS: Epidemiology, clinical feature, diagnosis, and therapy. *Acta Trop. Nov*;187:257-263.
4. **Mainali, N.R.; Quinlan, P.; Ukaigwe, A. and Amirishetty, S. (2013):** Cryptosporidial diarrhea in an immune-competent adult: role of nitazoxanide. *J. Commu. Hosp. Int. Med. Perspect.* 3, 3/4:10- 9.
5. **Amadi, B.; Mwiya, M.; Musuku, J.; Watuka, A. and Sianongo, S.(2002):** Effect of nitazoxanide on morbidity and mortality in Zambian children with cryptosporidiosis: a randomized controlled trial. *Lancet* 360:1375-80.
6. **Amadi, B.; Mwiya, M.and Sianongo, S. (2009):** High dose prolonged treatment with nitazoxanide is not effective for cryptosporidiosis in HIV positive Zambian children: a randomized controlled trial. *BMC Infect Dis.*; 9:195.
7. **Castellanos, G.A. (2013):** A novel calcium-dependent protein kinase inhibitor as a lead compound for treating cryptosporidiosis. *J Infect Dis*;208(8):1342–8.
8. **Ndao, M . (2013):** A cysteine protease inhibitor rescues mice from a lethal *Cryptosporidium parvum* infection. *Antimicrob Agents Chemother*;57(12):6063–73.
9. **Sun, Q.;; Cibas ,E.S.;Huang, H.; Hodgson ,L . and Overholtzer, M.(2014):**Induction of entosis by epithelial cadherin expression *Cell Res* Nov;24(11):1288-98.
10. **Kumar, V.P. (2014) :** Structural studies provide clues for analog design of specific inhibitors of *Cryptosporidium hominis* thymidylate synthase-dihydrofolate reductase. *Bioorg Med Chem Lett*;24(17):4158.
11. **Carl, P.;Weiner,M.D.;; MBA.;and FACOG. (2009):**Drugs for pregnant and lactating women. *science direct.* ;(2): p841-965.
12. **Sangun,L.; Melanie, G.; Don,G.; Gillian ,B.; Christopher, D.Huston.et al. (2019) :**Piperazine-Derivative MMV665917: An Effective Drug in the Diarrheic Piglet Model of *Cryptosporidium Hominis*. *J Infect Dis*; 19;220(2):285-293..
13. **Henriksen, S.A. and Pohlenz, J.F.L. (1981):** Staining of cryptosporidia by Modified Zeil Nelseen technique.*Acta Vet.Scand*;22:594-6.
14. **Tzipori, S.; McCarteny, E.; Lawson, G.H.K.; Rowland, A.C. and Campbell,I.(1981) :**Experimental infection of piglets with *cryptosporidium*. *Res.Vet*; 31:358-68.

15. **Platts-Mills, J.A.; Babji, S. and Bodhidatta, L. (2015):** MAL-ED Network Investigators. Pathogen-specific burdens of community diarrhoea in developing countries: a multisite birth cohort study (MAL-ED). *Lancet Glob Health.*; 3: e564–75.
16. **Korpe, P.S.; Haque, R. and Gilchrist, C. (2016):** Natural history of cryptosporidiosis in a longitudinal study of slum-dwelling Bangladeshi children: association with severe malnutrition. *PLoS Negl Trop Dis.*; 10: e0004564.
17. **Striepen, B. (2013):** Parasitic infections: time to tackle cryptosporidiosis *Nature.*;503:189–91.
18. **Atia, M.M.; Abdul Fattah, M.M.; Abdel Rahman, H.A.; Mohammed, F.A. and Al-Ghandour, A.M.F. (2016):** Assessing the efficacy of nitazoxanide in treatment of cryptosporidiosis using PCR examination. *J Egypt Soc Parasitol* 46(3):683–692.
19. **Checkley, W.; White, A.C. Jr.; Jaganath, D.; Arrowood, M.J.; Chalmers, R.M.; Chen, X.M. et al.(2015):** A review of the global burden, novel diagnostics, therapeutics, and vaccine targets for *cryptosporidium*. *Lancet Infect Dis.*; 15(1):85–94.
20. **Keusch, G.T.; Rosenberg, I.H.; Denno, D.M.; Duggan, C.; Guerrant, R.L. and Lavery, J.V. (2013):** Implications of acquired environmental enteric dysfunction for growth and stunting in infants and children living in low- and middle-income countries. *Food Nutr Bull.*;34(3):357–364.
21. **Van vorish ,w.c .; Adams, J.H.; Adelfio, R.; Ahyong ,V .; Akabas ,M.H . and Alano, P. et al.(2016):** Open source drug discovery with the Malaria Box compound collection for neglected diseases and beyond. *PLoS Pathog* 12:e1005763.
22. **Stebbins,E.;Rajiv,S.;Jumani1,2.;ConnorKlopper1.;JohnBarlow3.; PeterMiller1. et al. (2018):** Clinicalandmicrobiologiccefficacyofthepiperazine-baseddrugleadMMV665917inthedairycafcryptosporidiosismodel. *plos journal.*;1-10.
23. **Jumani, R.S.; Bessoff, K.; Love, M.S.; Miller, P.; Stebbins, E.E.; Teixeira, J.E. et al.(2018):** A Novel Piperazine-Based Drug Lead for cryptosporidiosis from the Medicines for Malaria Venture Open-Access Malaria Box. p1-9 .
24. **Mostafa,N.E.;AbdelHamed,E.F.;Fawzy,E.M.;Zalat,R.S.; Hayam E Rashed,H.E. et al.(2018):** The new trend in the treatment of experimental cryptosporidiosis and the resulting intestinal dysplasia *Colorect. Cancer* 7(4).
25. **Desautels, K.S.;Renteria,A.E.; Camargo,F.V.; Thomas Z. Di Lenardo, T.Z. and Hazaa,k.k et al .(2016):** Efficacy of garlic and onion oils on murin experimental *Cryptosporidium parvum* infection. *Al-Anbar J. Vet. Sci.*, Vol.: 9 No. (2), 2016 ISSN: 1999-6527 69 I.
26. **Hazaa,k.k.; Al-Taai, N.A.; Khalil,N.Kh. and. Zakri,A.M.M.(2016):** Efficacy of garlic and onion oils on murin experimental *Cryptosporidium parvum* infection. *Al-Anbar J. Vet. Sci.*, Vol.: 9 No. (2), 2016 ISSN: 1999-6527 69 I.
27. **Soufy1, H.; El-Beih2, N.M.; Nasr1, S.M.; Abd El-Aziz1, T. H.; Khalill, F.A.M.; Ahmed3. et al.(2017):** Effect of Egyptian propolis on cryptosporidiosis in immunosuppressed rats with special emphasis on oocysts shedding, leukogram, protein profile and ileum histopathology. *Asian Pacific Journal of Tropical Medicine.*;10(3):253-262.
28. **Bejan, A.; Bolfa, P.; Magdas, C.; Pop, R.; Mircean; Viorica. Et al.(2011):** Histopathological and immunofluorescence characterization of *cryptosporidium*

- parvum* natural infection in goat kids from Romania. Acta Veterinaria (Beograd).; Vol. 61, No. 5-6, 609-619, 201.
29. **Abdoua, A. g.; Harbab, N.M.; Afifib, A.F. and Elnaidanyc ,N.F . (2013):** Assessment of *Cryptosporidium parvum* infection in immunocompetent and immunocompromised mice and its role in triggering intestinal dysplasia International Journal of Infectious Disease. ;(17): e593-e600.
30. **Hussien , S.M.M.; Abdella,O.H.; AbuHashim,O.H.; Aboshiesha,G.A.; Taha, M.A.A. and El-Shemy,A.S. et al.(2013):** Comparative study between the effect of nitazoxanide and paromomycine in treatment of cryptosporidiosis in hospitalized children. J Egypt Soc Parasitol: Aug;43(2):463-70.